



**FOOT AND MOUTH
DISEASE**

Pocket Guide

Domestic Swine

Acknowledgements

This pocket guide was developed to enhance vesicular disease surveillance in swine through cooperative agreement Q09-9119-1270 from USDA-APHIS. The cooperative effort included contributions from the Animal and Plant Health Inspection Service (APHIS), the American Association of Swine Veterinarians, National Pork Board, and the Center for Food Security and Public Health at Iowa State University.



The authors would like to credit the USDA APHIS Foreign Animal Disease Diagnostic Laboratory and the Department of Homeland Security (DHS) Visual Information Service at the Plum Island Animal Disease Center (PIADC) for the use of the sequential images of domestic and feral swine infected with foot and mouth disease virus. We would like to thank the DHS Animal Resources Unit at PIADC for caring for these animals during this project.

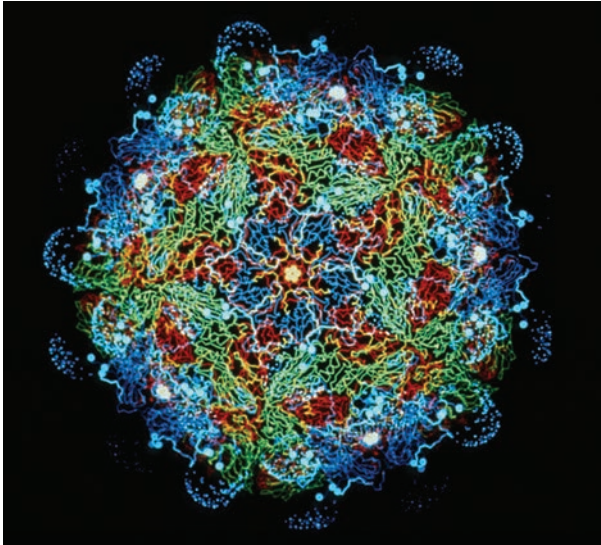
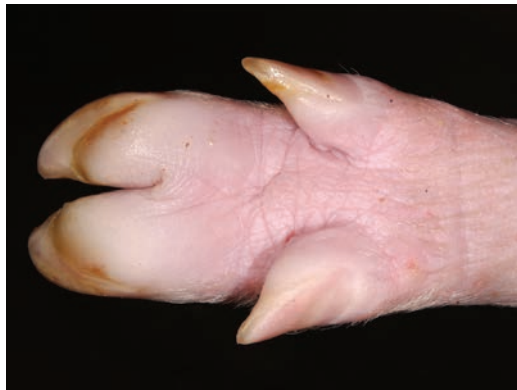
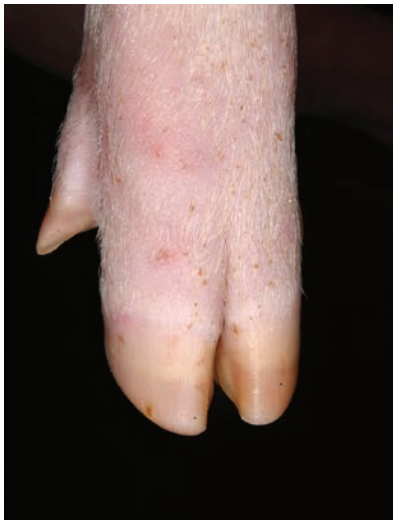

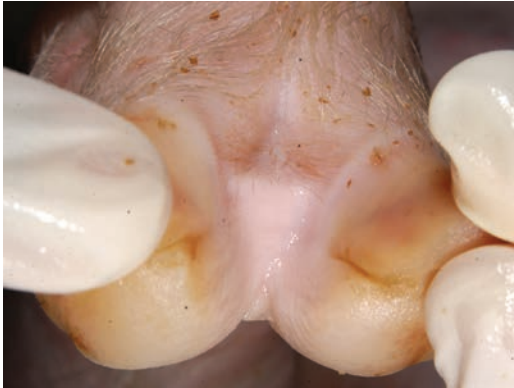Photo credit: Dr. Fred Brown

This set of photos was taken by the personnel at Plum Island Animal Disease Center. Infected animals were inoculated with foot and mouth disease (FMD) virus strain A24 Cruzeiro. The pigs depicted in the following photographs were allowed contact with infected animals 48 hours post-inoculation and remained with the inoculated animals for the duration.

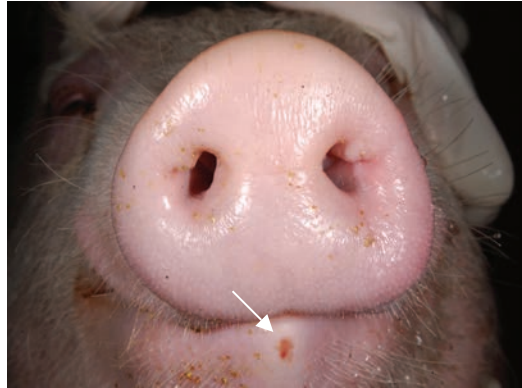
Domestic Swine Day 1



- ▲ Blanched swollen hoof pads.
- ◄ No visible lesions.

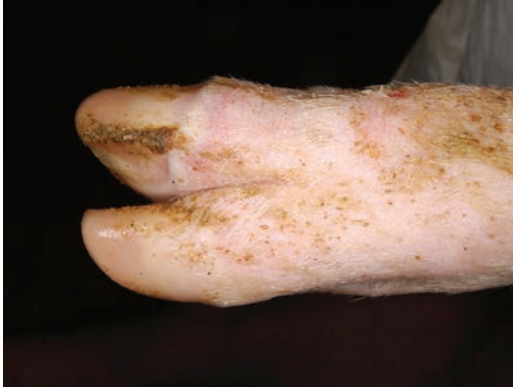

▲ No visible lesions.

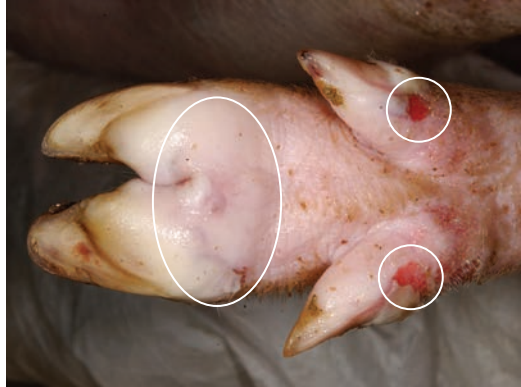


▲ Erosion of tip of lower lip.

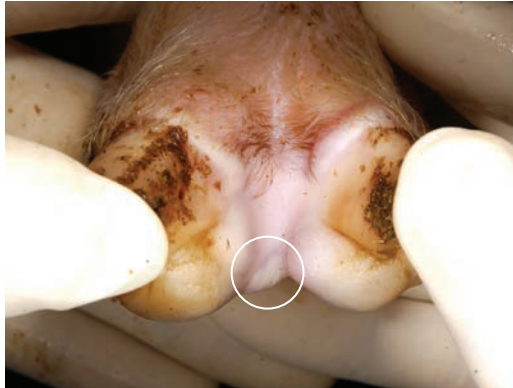
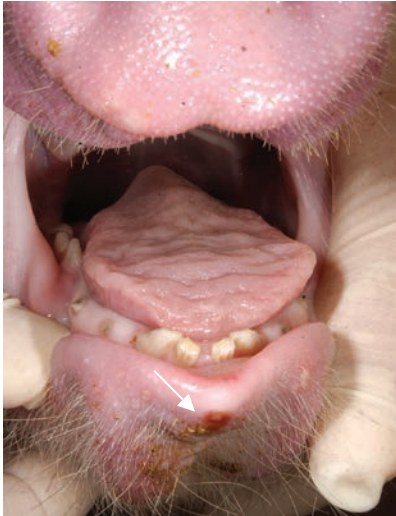Domestic Swine **Day 2**



▲ Blanching of coronary band.

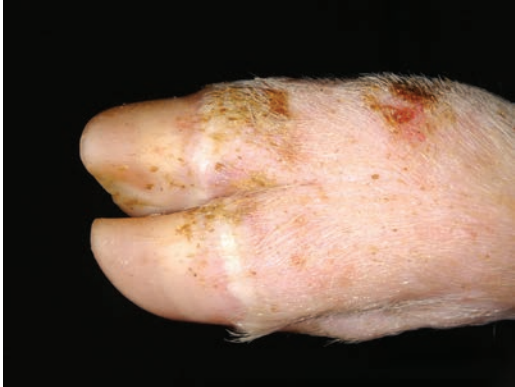

▲ Vesicles of hoof pads and ruptured vesicles of dewclaws.

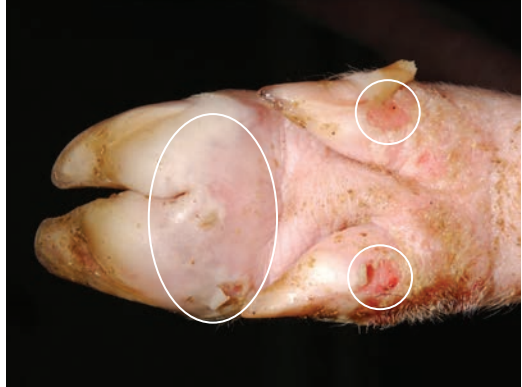

- ▲ Vesicle in interdental area.
- ◄ Erosion of tip of lower lip.

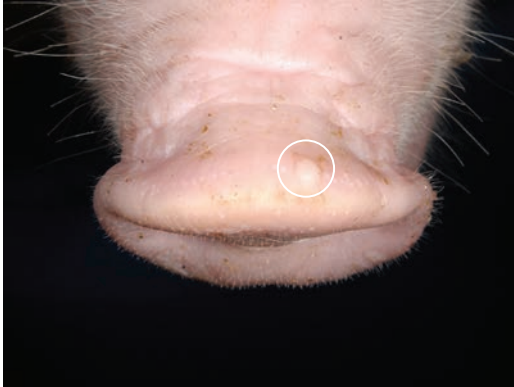
Domestic Swine Day 3



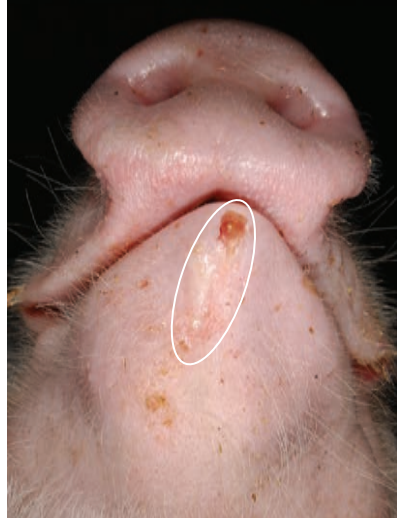
▲ Blanched coronary band with abrasions of skin over knuckle.



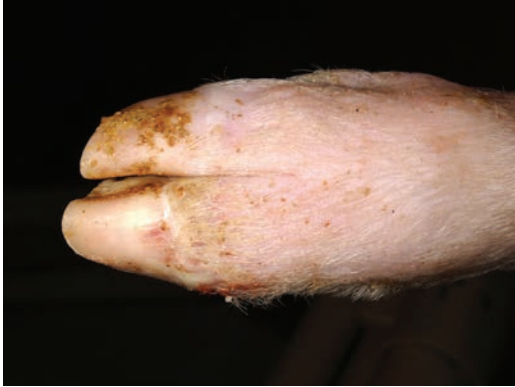▲ Vesicles of hoof pad and ruptured vesicles of dewclaws.



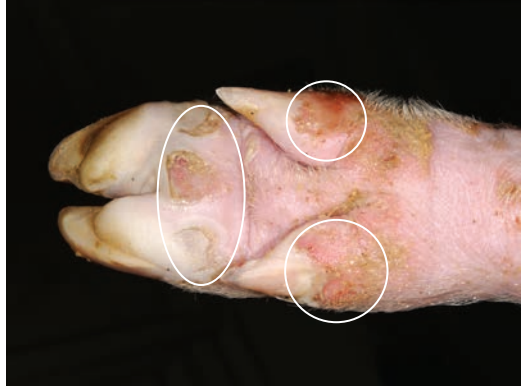- ▲ Vesicle on top of snout.
- ▶ Vesicle and erosion on lower lip.



Domestic Swine **Day 4**

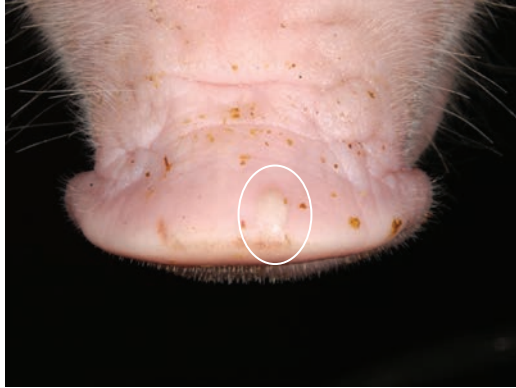
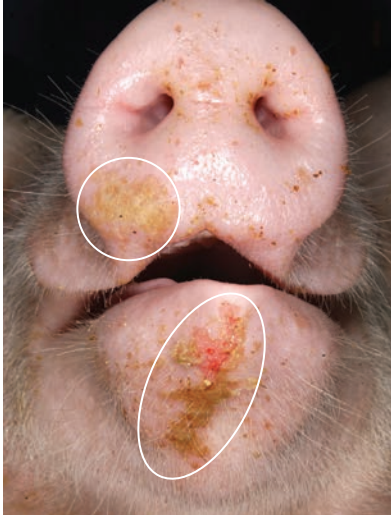
▲ Blanched coronary band.



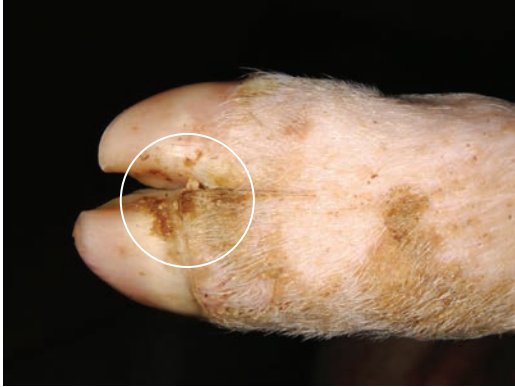▲ Ulcerations and erosions from ruptured vesicles.

Domestic Swine **Day 4**

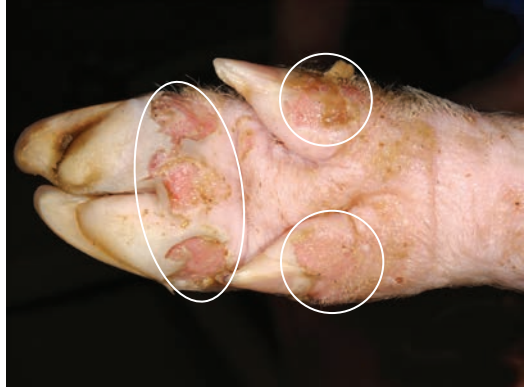

- ▲ Vesicle on top of snout.
- ◀ Erosion of lower lip and snout with fibrin.

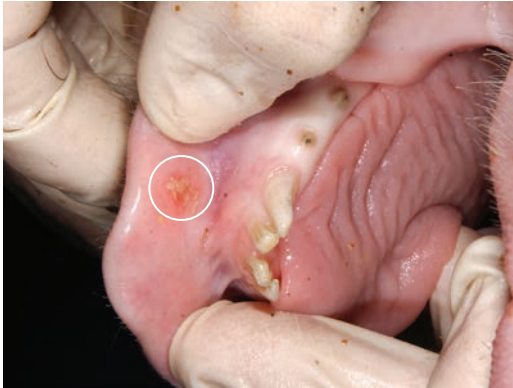
Domestic Swine **Day 6**



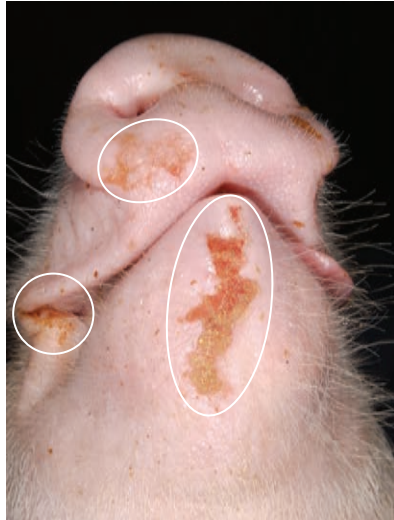▲ Necrosis of coronary band with crusting.



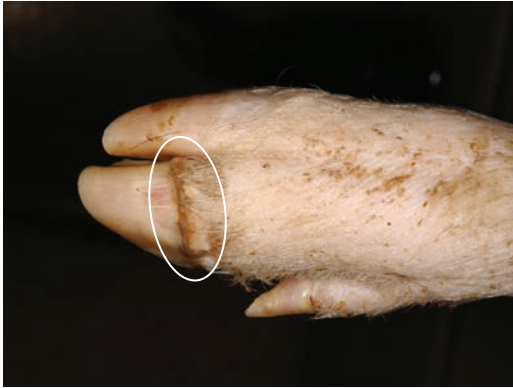▲ Multifocal deep ulcers, hoof pad and dewclaws at the coronary band.



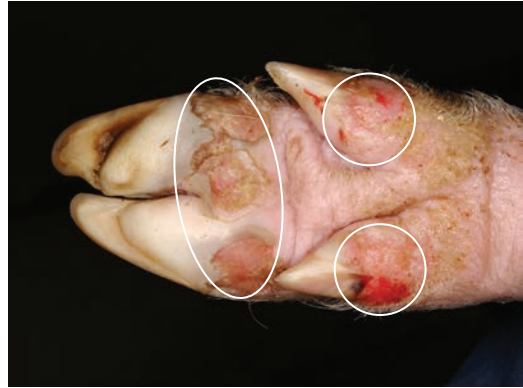
- ▲ Erosion with fibrin deposition.
- ▶ Ulcerative and erosive lesions of the skin on the lower jaw, lower snout, and unilateral commissure.



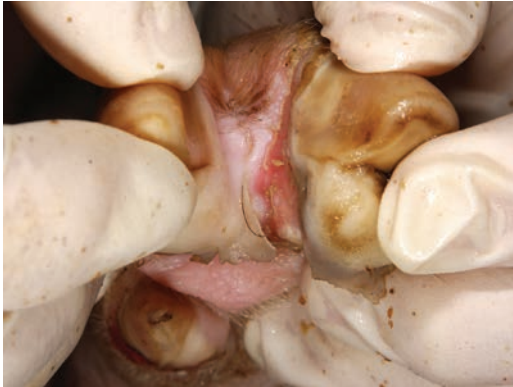Domestic Swine **Day 7**



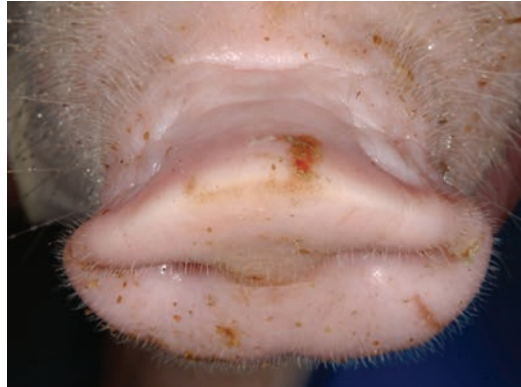▲ Necrosis of coronary band with crusting.



▲ Multifocal deep ulcers, hoof pad and dewclaws at the coronary band.

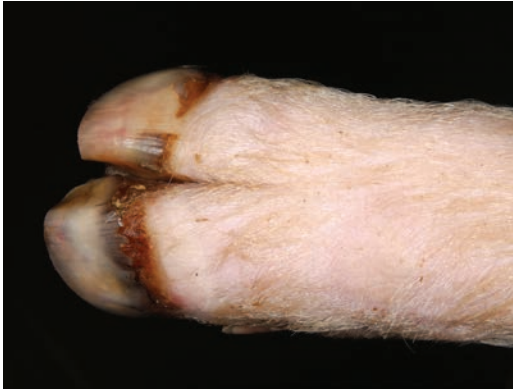

▲ Interdigital ulceration at coronary band.

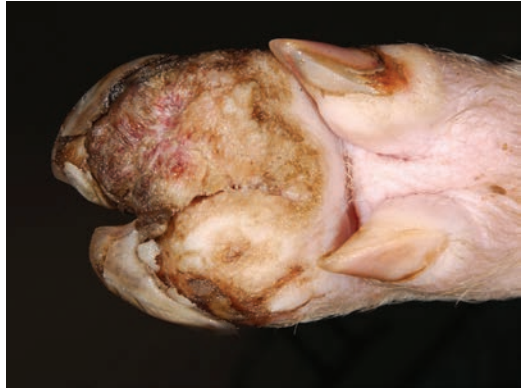

▲ Ruptured vesicle on top of snout.

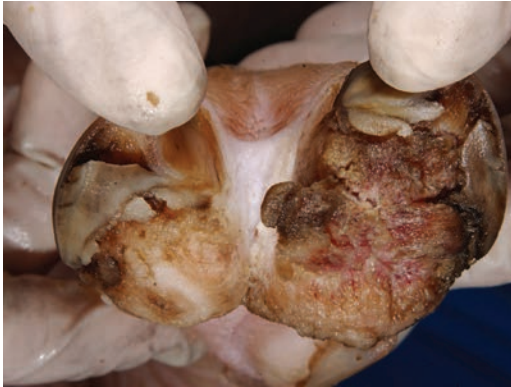Domestic Swine **Day 19**



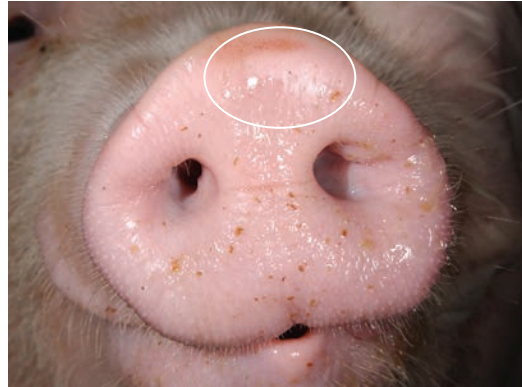
- ▲ Necrosis of coronary band with hoof sloughing and new hoof growth.



- ▲ Bilateral necrosis and ulceration with sloughing of hoof wall.

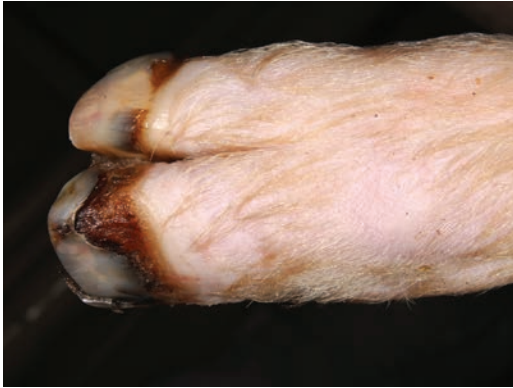

▲ Bilateral necrosis and ulceration with sloughing of hoof wall.

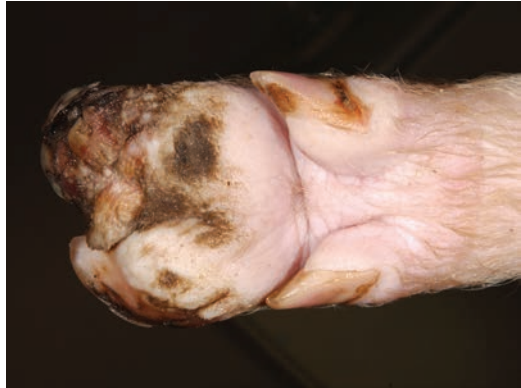

▲ Healing ruptured vesicle.

Domestic Swine Day 26

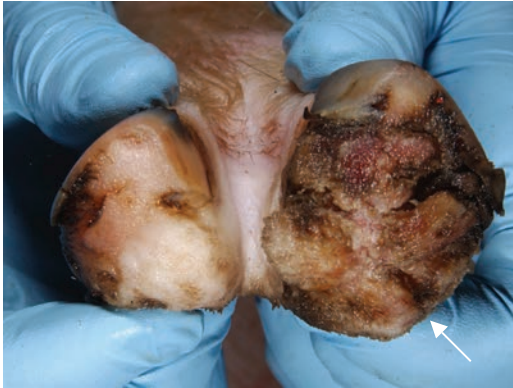

▲ Necrosis of coronary band with hoof sloughing and new hoof growth.

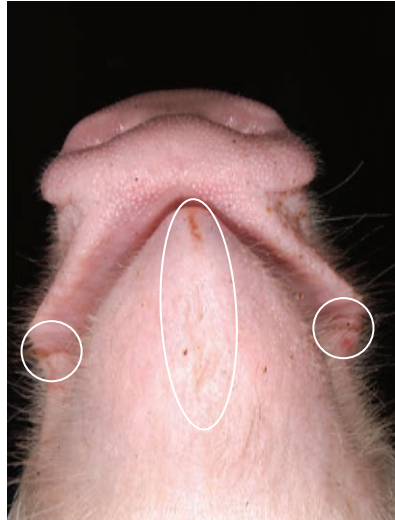


▲ Bilateral necrosis and ulceration with sloughing of hoof wall.

Domestic Swine **Day 26**



- ▲ Bilateral necrosis and ulceration with sloughing of hoof wall.
- ▶ Healed erosion of lower lip.



Procedures to follow if you suspect a Foreign Animal Disease

1. Make “the Call.”

Call the federal Assistant District Director (ADD) for your state or your State Animal Health Official (SAHO). Contact information for your ADD or SAHO can be obtained by calling (866) 536-7593. You can also call the USDA Emergency number (800) 940-6524 (24 hours) for assistance.

2. Discuss How to Proceed.

The ADD or SAHO will let you know approximately when the Foreign Animal Disease Diagnostician (FADD) will conduct a site visit. You should discuss precautions to take concerning people movement and contact with animals while waiting for the FADD to arrive. They will also want to start gathering information from you and the producer. Discuss the next steps to follow with the ADD or the SAHO you have contacted.

Information will be held confidential to prevent unwarranted sharing of information during the investigation.

Some of the concerns you may discuss over the phone or when the FADD arrives include the following:

- When were the first lesions evident?
- When were animals last transported from the farm and what was their destination?
- When were these animals delivered to the farm and where did they come from?
- Does this producer care for other livestock?
- How many employees work at this site?
- Do the employees have livestock at home?
- Is equipment shared between sites or with neighbors?
- Does the producer grind his own feed or when was the last delivery of feed?
- Have there been any foreign visitors to the farm?
- Have any employees recently visited a foreign country?
- Are employees permitted to consume meat in the livestock buildings?

3. Assisting the FADD

When the FADD arrives, communication will continue between the FADD, the veterinarian, and the producer. Many questions will need to be answered during the investigation. Be assured that there will be a constant stream of communication to keep you informed of the procedures for sample testing and the timeframe involved.

Thank you to all the individuals who contributed to this publication.

USDA APHIS Plum Island Animal Disease Center (PIADC)

Foreign Animal Disease Diagnostic Laboratory

Samia Metwally

Andrew Fabian

Heather Leibrecht

Fawzi Mohamed

Marylou Berninger

Consuelo Carrillo

Heather Petrowski

Gregory Mayr

William White

Alexa Bracht

Karen Moran

Ping Wu

USDA ARS PIADC Foreign Animal Disease Research Unit

Luis Rodriguez

Juan Pacheco

Ethan Hartwig

USDA APHIS Wildlife Services

Seth Swafford

Janean Romines

Brandon Schmit

Mark Lutman

Darrell Kavanaugh

Mike Marlow

Kerri Pedersen

David Marks

Department of Homeland Security PIADC Visual Information Service

Kathy Apicelli

Ethan Macnow

Department of Homeland Security PIADC Animal Care and Resource Unit

Jeffrey Babcock

Amber Sabrosky

Anthony Gonzalez

Ralph Soto

Philip Doucett

John Brown

USDA APHIS Veterinary Services

David Pyburn

Center for Food Security and Public Health

Iowa State University College of Veterinary Medicine

Jim Roth

Claire Andreasen

Alex Ramirez

Pam Zaabel

Katlyn Harvey

American Association of Swine Veterinarians

Harry Snelson

National Pork Board

Patrick Webb

Paul Sundberg

Lisa Becton

Mike King



**FOOT AND MOUTH
DISEASE**

Pocket Guide

Feral Swine

Acknowledgements

This pocket guide was developed to enhance vesicular disease surveillance in swine through cooperative agreement Q09-9119-1270 from USDA-APHIS. The cooperative effort included contributions from the Animal and Plant Health Inspection Service (APHIS), the American Association of Swine Veterinarians, National Pork Board, and the Center for Food Security and Public Health at Iowa State University.



The authors would like to credit the USDA APHIS Foreign Animal Disease Diagnostic Laboratory and the Department of Homeland Security (DHS) Visual Information Service at the Plum Island Animal Disease Center (PIADC) for the use of the sequential images of domestic and feral swine infected with foot and mouth disease virus. We would like to thank the DHS Animal Resources Unit at PIADC for caring for these animals during this project.

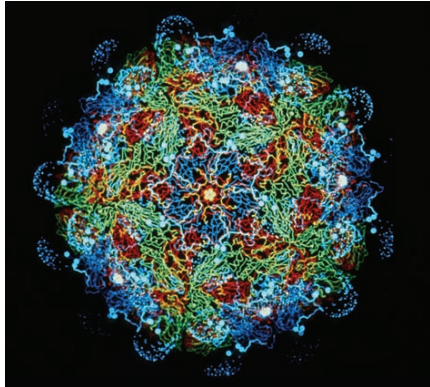


Photo credit: Dr. Fred Brown

This set of photos was taken by the personnel at Plum Island Animal Disease Center. Infected animals were inoculated with foot and mouth disease (FMD) virus strain A24 Cruzeiro. The pigs depicted in the following photographs were allowed contact with infected animals 48 hours post-inoculation and remained with the inoculated animals for the duration.

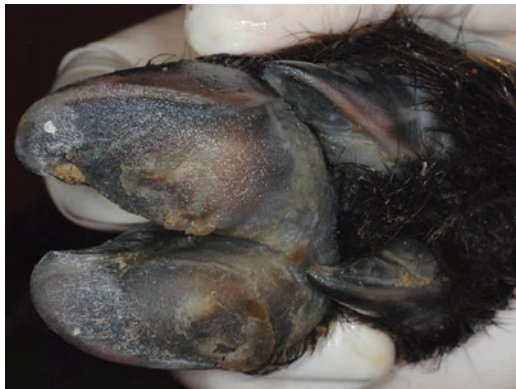Feral swine (*Sus scrofa*) populations in the United States are comprised of a continuum of genetic diversity ranging from escaped domestic pigs (*Sus scrofa domesticus*) to Eurasian wild boar (*Sus scrofa scrofa*) and the hybrids of these subspecies. The following series of photos represent clinical signs of FMD in hybridized feral swine whose genetics are very close to pure Eurasian wild boar heritage. Please note that feral swine may have thicker skin and darker pigmentation which makes vesicular lesions more difficult to detect than in their domestic swine counterparts.

If a case of FMD is suspected in wildlife, call the Wildlife Services Hotline (866) 4 USDA-WS or (866) 487-3297.

Feral Swine **Day 1**



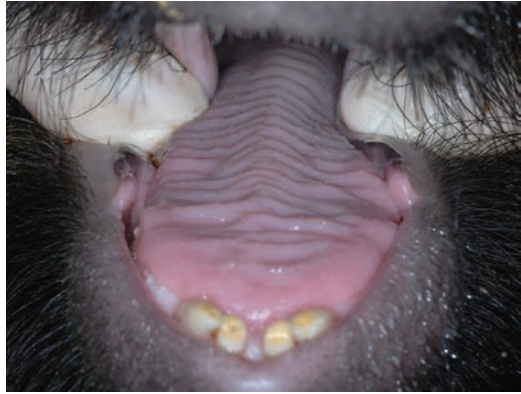▲ No visible lesions.



▲ No visible lesions.



▲ No visible lesions.



▲ No visible lesions.

Feral Swine Day 2



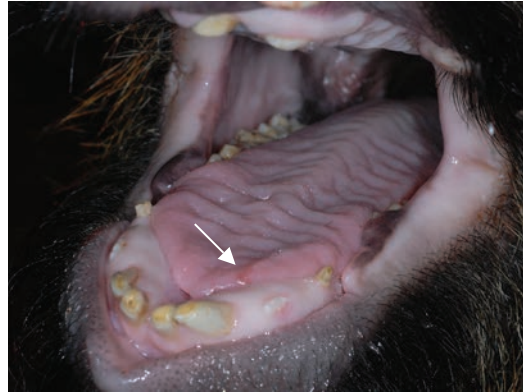▲ No visible lesions.



▲ No visible lesions.



▲ No visible lesions.

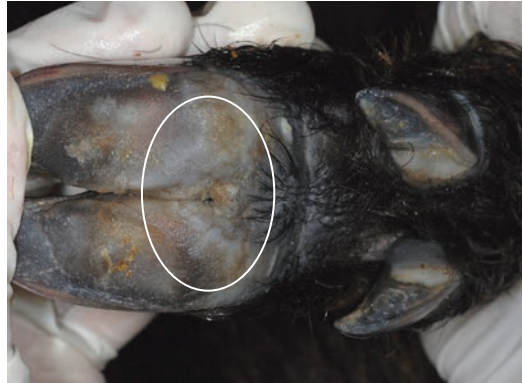

▲ Small early vesicle on tongue edge.

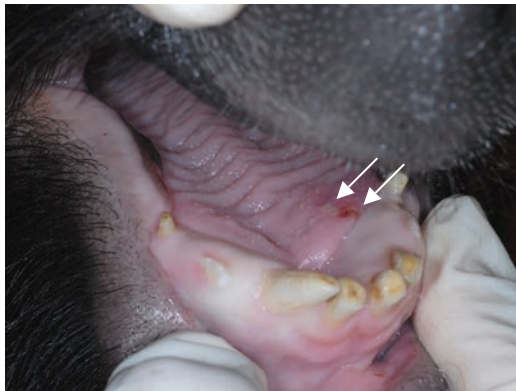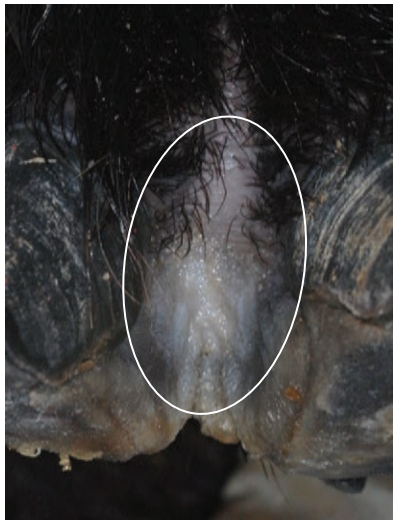Feral Swine Day 3



▲ Blanched coronary band.

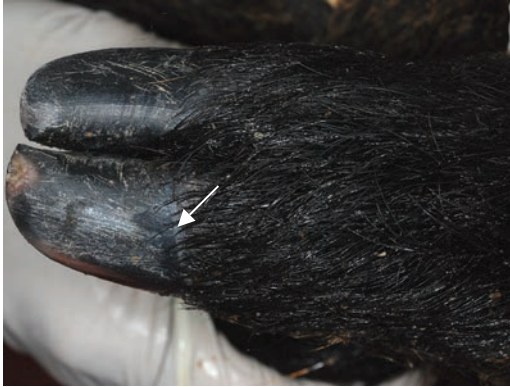

▲ Pale areas and swelling on the area of hoof pad.

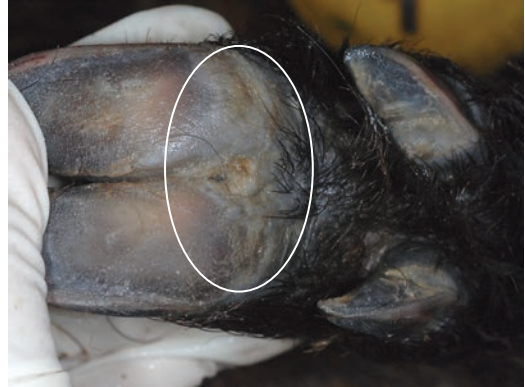

- ▲ Focal ulcer and adjacent early vesicle on the dorsal tongue.
- ◀ Blanched interdental space.

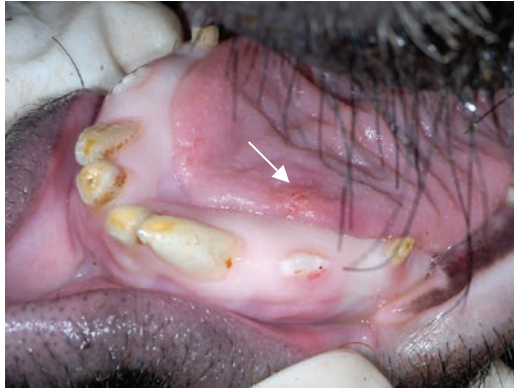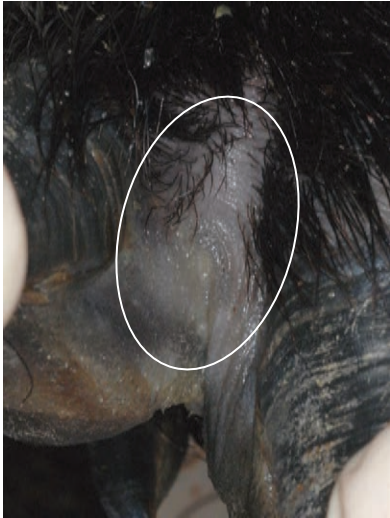Feral Swine **Day 4**



▲ Blanching of coronary band.

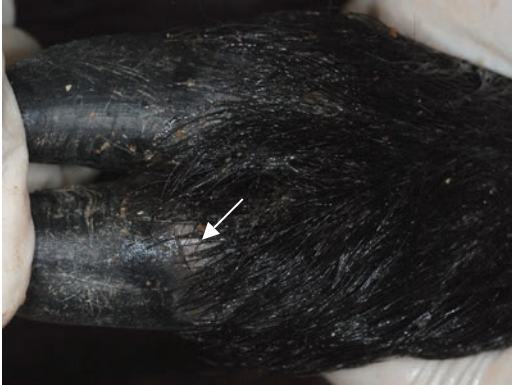

▲ Raised pale area of hoof pad.

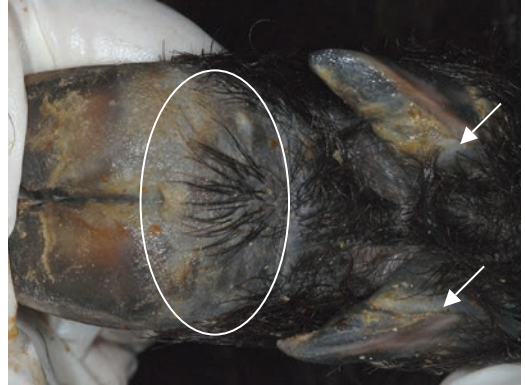

- ▲ Focal ulcer and adjacent early vesicle on the dorsal tongue.
- ◀ Blanched interdental space.

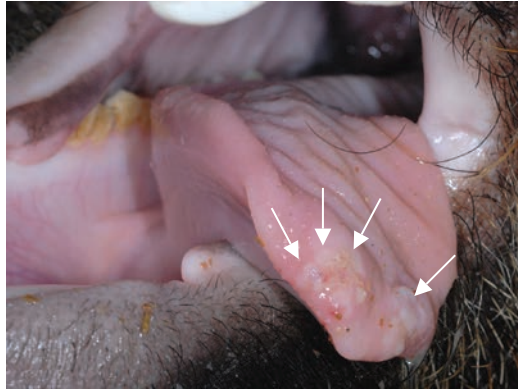
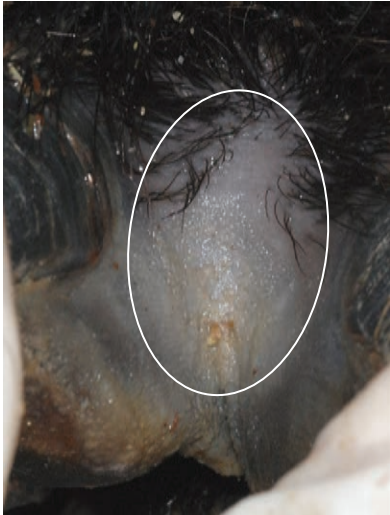Feral Swine Day 6



▲ Vesicle at coronary band.

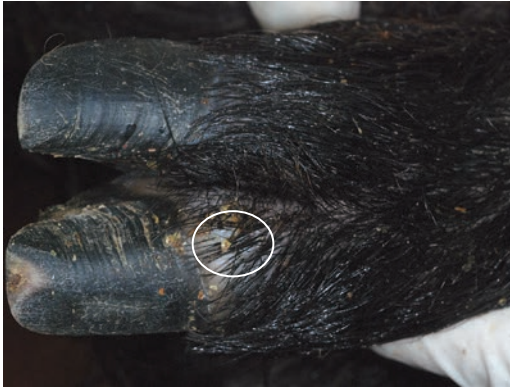

▲ Blanched hoof pad and coronary bands of dewclaws.

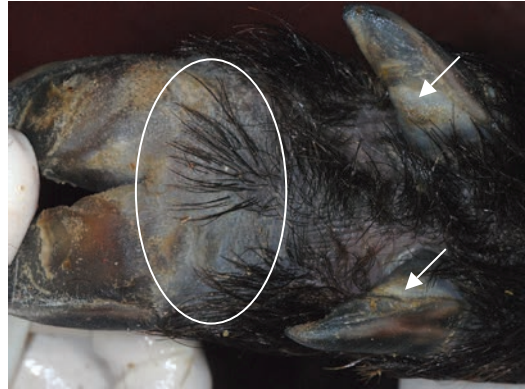


- ▲ Blanched tissue with erosions and vesicles on rostral area of tongue.
- ◀ Blanched interdental space.

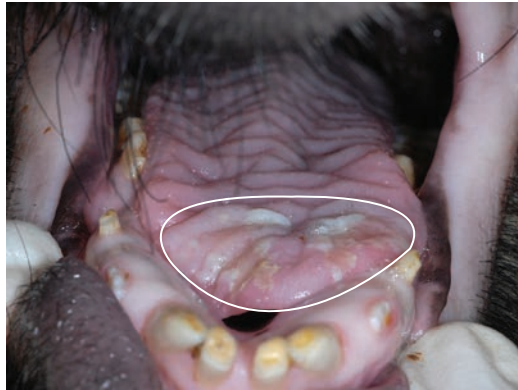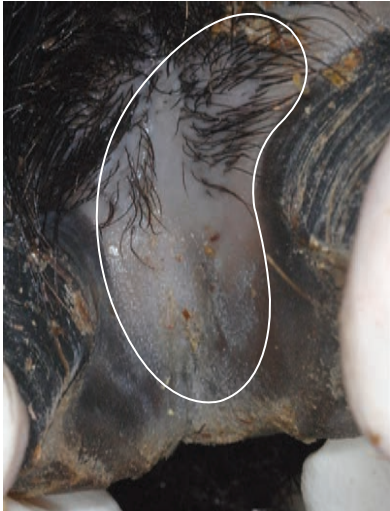Feral Swine Day 7



▲ Vesicle at coronary band.



▲ Blanched hoof pad and coronary bands of dewclaws.

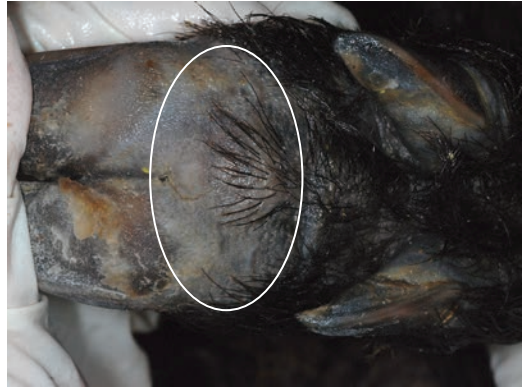

- ▲ Tongue with erosions and sloughing epithelium.
- ◀ Blanched interdigital space.

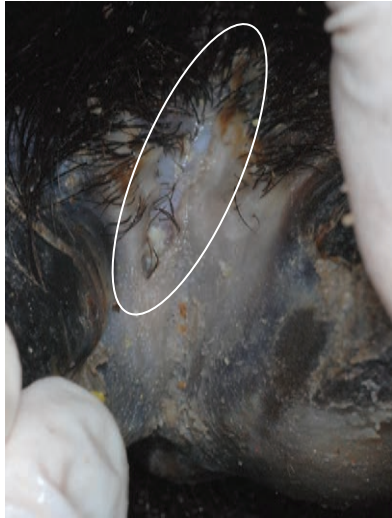Feral Swine Day 12



▲ Crusting of coronary band.

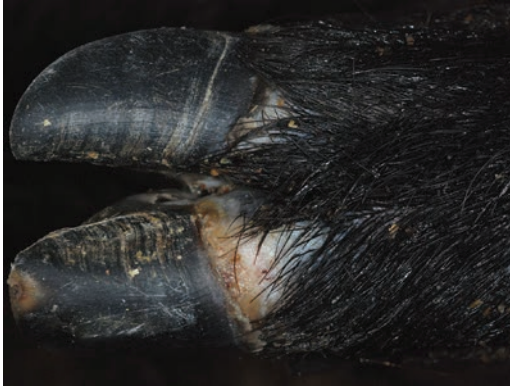

▲ Blanched hoof pad.

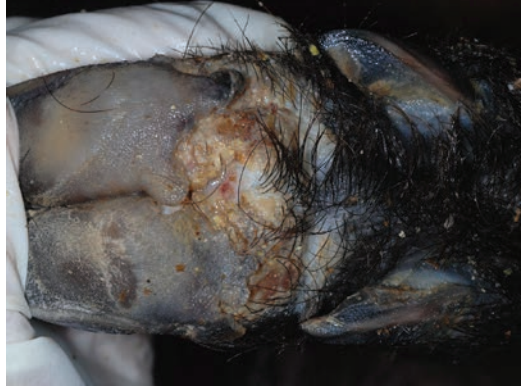

- ▲ No visible lesions.
- ◄ Rupture of skin in interdigital space.

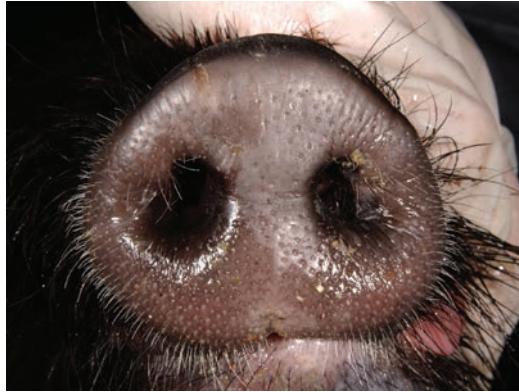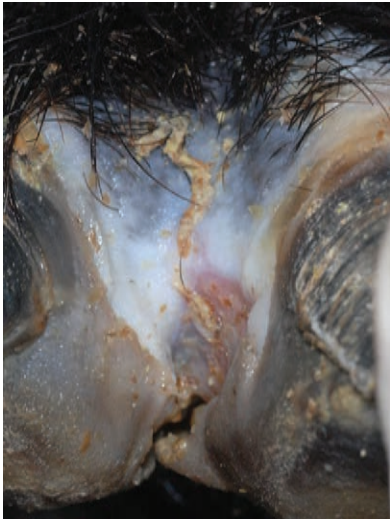Feral Swine Day 19



▲ Ulceration and necrosis at coronary band with early sloughing of hoof.



▲ Extensive hoof pad ulceration with crusting.

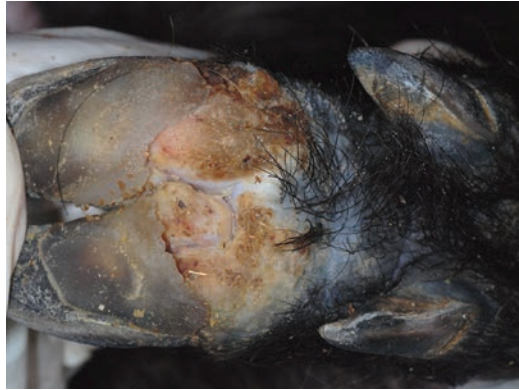


- ▲ No visible lesions.
- ◀ Necrosis of interdigital space with ulceration and crusting.

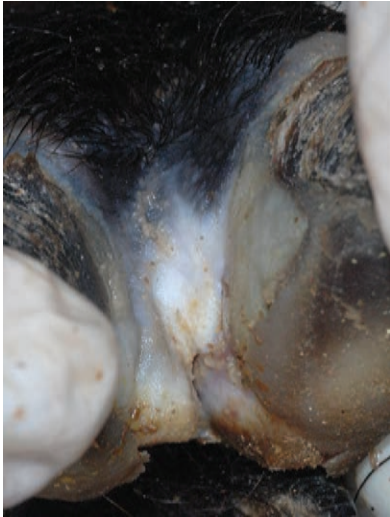Feral Swine Day 26



▲ Healing coronary band with new hoof growth.



▲ Extensive hoof pad ulceration with crusting.



- ▲ Ruptured vesicle on top of snout.
- ◀ Healing of interdigital space.

Procedures to follow if you suspect a Foreign Animal Disease

1. Suspect FMD in feral swine.

A pig that has any of the following:

Vesicles, erosions or ulcerations on the mouth (snout, muzzle, tongue, dental pad, gum, cheek, hard palate, soft palate); and vesicles, erosions, ulcerations or sloughing of digital horn on at least one foot.

Even though the lesions shown here are characteristic of FMD, the first visible sign may be as simple as a lame pig.

2. Make “the Call.”

Call the federal Assistant District Director (ADD) for your state or your State Animal Health Official (SAHO). Contact information for your ADD or SAHO can be obtained by calling (866) 536-7593. You can also call the USDA Emergency number (800) 940-6524 (24 hours) for assistance. For assistance with feral swine related damage or disease issues, call Wildlife Services Hotline at (866) 487-3297.

3. Discuss How to Proceed

The SAHO or ADD may require additional information before making the determination to begin a foreign animal disease field investigation. In some remote cases, the SAHO or ADD may ask that you collect samples and send them to the laboratory, but this determination will be made only if you have the ability to adequately decontaminate the sample container, yourself, and all of your equipment before leaving the area. In most cases of a suspected foreign animal disease consistent with FMD, you will remain on site until appropriate biosecurity measures can be taken to prevent further spread of the suspected disease.

Some of the concerns you may discuss over the phone include:

- How were the feral swine captured and could the capture technique or length of time spent in the trap have contributed to the development of the suspect clinical signs?
- Are the feral swine alive or have they been euthanized?
- Are the feral swine exhibiting signs of lameness or other health problems?
- Are there livestock in the area?
- Are you on public or private land?
- Do you have the resources to allow you to stay on site until the investigation is completed?